

VAGINAL MESH EXTRUSION ASSOCIATED WITH USE OF MENTOR TRANSOBTURATOR SLING

ANDREW L. SIEGEL

ABSTRACT

Objectives. To describe my experience of vaginal mesh extrusion using the monofilament polypropylene transobturator sling, the Mentor ObTape. The Mentor ObTape was the first transobturator sling developed as an alternative to the retropubic commercially available suburethral slings for providing mid-urethral support as treatment of female stress urinary incontinence.

Methods. Thirty patients underwent transobturator suburethral sling placement for anatomic stress urinary incontinence using the ObTape from October 2003 to January 2005. A retrospective chart review was performed to retrieve data on the safety, efficacy, complications, and outcomes using this product.

Results. Six patients (20%) to date have presented with defective vaginal healing manifested by extrusion of the sling material. Five patients required surgical removal of the sling material, and one underwent a trial of conservative management. No urethral erosions were noted.

Conclusions. In my experience, the Mentor ObTape sling, which uses a nonwoven, minimally elastic, micropore, monofilament polypropylene mesh, incurs an unacceptably high rate of defective vaginal wound healing and mesh extrusion. UROLOGY 66: 995–999, 2005. © 2005 Elsevier Inc.

The concept of a sling for the management of stress incontinence was first introduced in the early 1900s using the gracilis muscle.¹ Autologous grafts have provided high success rates; however, their use has been limited by harvest site morbidity, including pain, hernia, and longer recovery times. As such, many modifications of the autologous sling have been made aimed at maintaining the high success rates while reducing the morbidity.

Petros² and Ulmsten and Petros³ are primarily responsible for a major paradigm shift, including the use of synthetic tape, mid-urethral placement, tension-free support, fixation by friction, and the use of local anesthesia. Synthetic slings obviate the need for harvesting autologous tissue and are associated with high success rates similar to those with nonsynthetic materials. This “disruptive technology” of new-age slings has resulted in changing and re-creating the marketplace and a remarkably

rapid evolution, adoption, and conversion. However, despite many potential advantages, synthetic slings are clearly associated with greater rates of vaginal/urethral erosions (0.2% to 22%).^{4,5}

Polypropylene tapes have emerged as the standard because of the lower reported rates of erosion/extrusions (0% to 5%) compared with other forms of synthetic slings.⁶ As an alternative to the commercially available polypropylene retropubic slings, transobturator slings have emerged as potentially less-invasive alternatives. First reported by Delorme⁷ in 2001, the transobturator approach was conceived to avoid the retropubic space in a patient who had undergone previous pelvic surgery. This approach, with a hammock-like sling configuration versus the swing-like configuration of the retropubic approach affords theoretical advantages, including lower likelihood of bladder, bowel, or vascular injury and potentially less postoperative voiding dysfunction. The ObTape, manufactured by Mentor (Santa Barbara, Calif), was the first-generation transobturator tape, but recently many transobturator alternatives have become available (Fig. 1). Commercially available transobturator tapes include theTVT-O by Johnson & Johnson/Gynecare, Monarc by American Medical Systems, Obtryx by Boston Scientific, and Uretex-TO by Bard. In this report, I provide my experience with

From the Department of Urology, University of Medicine of New Jersey, USA ; and Continence Center, Hackensack University Medical Center, Hackensack, New Jersey

Reprint requests: Andrew L. Siegel, M.D., Department of Urology, University of Medicine of New Jersey, Hackensack Mediplex Plaza, 20 Prospect Avenue, Suite 715, Hackensack, NJ 07601. E-mail: incontinencedoc@optonline.net

Submitted: February 12, 2005, accepted (with revisions): May 9, 2005




FIGURE 1. (Top) TVT macropore, elastic polypropylene tape. (Bottom) Mentor ObTape micropore, inelastic tape.

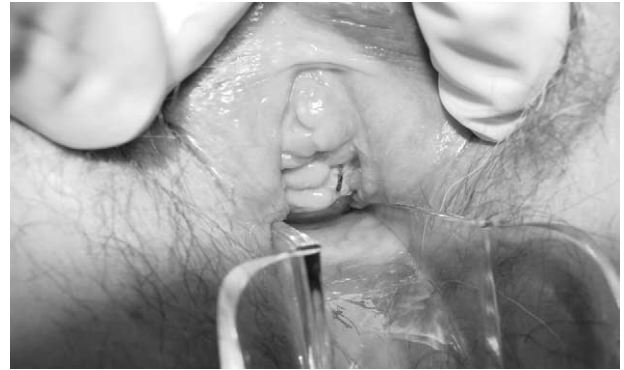

FIGURE 2. Vaginal extrusion of Mentor ObTape mesh. Note midline marking of mesh clearly visible on introital examination.

the use of the Mentor ObTape sling and report a high rate of defective vaginal healing and vaginal mesh extrusion.

MATERIAL AND METHODS

Between October 2003 and January 2005, 30 patients underwent placement of a Mentor ObTape transobturator sling. A retrospective review of all charts was performed. All patients had undergone a preoperative assessment consisting of a history and physical examination, Incontinence Quality of Life questionnaire, 24-hour incontinence and voiding diary, modified Marshall test, cystoscopy, and multichannel video-urodynamic examination. The Marshall test was performed by filling the bladder with 250 mL of water and asking the patient to perform a Valsalva maneuver and cough to induce the incontinence, followed by application of gentle suburethral support to test whether the incontinence was abolished.

All patients were treated with broad-spectrum prophylactic antibiotics preoperatively, intraoperative antibiotic irrigation, and postoperative antibiotics. Patients were positioned in an exaggerated dorsal lithotomy position, and after preparation and draping, the groin puncture sites were marked 2 cm superior to the urethral meatus and one fingerbreadth lateral to the genital-inguinal crease. The puncture sites and suburethral area were infiltrated with bupivacaine with epinephrine before making a 2-cm vertical anterior vaginal wall incision over the mid-urethra. The plane between the urethra and vagina was developed sharply and bluntly, and paraurethral dissection to the ischiopubic ramus was performed. After a groin stab incision at the designated site, the ObTape introducer was used to puncture the obturator membrane and was then passed through the paraurethral space under digital guidance. The sling was attached to the eyelet of the introducer, and the introducer was reversed out through the groin. The identical procedure was repeated on the opposite side. After cystoscopy confirmed no penetration of the bladder, bladder neck, or urethra, the tape tension was adjusted, excess tape was excised, and the vaginal and groin incisions were closed with 2-0 polyglactin suture and topical skin adhesive, respectively. After surgery, regular follow-up examinations were performed at 2 weeks, 6 weeks, and 12 months postoperatively.

RESULTS

Of the 30 patients who underwent placement of a Mentor ObTape sling, 6 (20%) have demonstrated midline vaginal mesh extrusion (Fig. 2). The presenting symptoms included serous vaginal dis-

charge in all 6 (100%), obturator abscess in 1 (17%), and penile pain associated with sexual intercourse with her husband in 1 (17%).

All patients underwent pelvic examination with a Sims speculum and cystourethroscopy. Five had extruded sling material visible in the midline of the anterior vagina, and one had developed a tender, fluctuant mass overlying the left groin site with purulent drainage 6 weeks postoperatively. One patient required vaginoscopy at cystoscopy to identify a small, subtle extrusion. Four patients required partial or complete sling removal and reported complete resolution of their symptoms. One patient underwent a trial of conservative management with topical estrogen cream. The last patient was scheduled for sling removal.

CASE 1

A 48-year-old healthy woman who underwent the ObTape sling procedure complained of persistent yellow vaginal discharge. Three months postoperatively, she stated that her husband felt "teeth" in her vagina during sexual intercourse. The pelvic examination revealed midline mesh extrusion. Conservative management was tried, but she ultimately required removal of the entire sling and placement of a secondary suburethral sling because of recurrent exertional incontinence.

CASE 2

A 48-year-old healthy woman who underwent the ObTape sling procedure complained of persistent yellow vaginal discharge. Six weeks postoperatively, the pelvic examination revealed a midline mesh extrusion. The mesh extrusion was initially managed with in-office excision of the extruded suburethral segment, followed by additional in-office trimming of more exposed sling. Follow-up revealed persistent exposed sling and recurrent incontinence, and she underwent sling removal and secondary sling placement.

CASE 3

A 75-year-old obese, diabetic woman had previously undergone cadaveric fascial suburethral sling placement with bone fixation and a suprapubic arc (SPARC) suburethral sling. Because of recurrent incontinence, she underwent an ObTape sling procedure, at which time she was found to have anterior vaginal wall suture granulomas that were excised at sling placement. Postoperatively, she complained of persistent vaginal staining and bleeding. The pelvic examination demonstrated a midline mesh extrusion. She was treated with in-office removal of the entire sling.

CASE 4

A 58-year-old obese woman had undergone cadaveric fascial suburethral sling placement with bone fixation 4 years previously. Thereafter, she developed recurrent anterior vaginal wall granulation tissue that had been managed with cauterizations and excisions. She underwent the ObTape procedure and simultaneous excision of additional granulation tissue. Two months postoperatively, she noted bloody vaginal discharge, and the pelvic examination revealed midline mesh exposure and an inflammatory mass involving the left obturator region. She was treated with antibiotics and warm soaks, but ultimately underwent complete removal of the sling and drainage of a left obturator abscess.

CASE 5

A healthy 61-year-old woman had undergone a Tyco Intra-Vaginal Slingoplasty suburethral sling 2 years previously and 6 months later noted bloody vaginal spotting. On pelvic examination, she was noted to have a midline mesh extrusion. Because of mild recurrent exertional incontinence, she underwent removal of the IVS sling and replacement with an ObTape sling. Two months postoperatively, she noted bloody vaginal discharge. The pelvic examination and cystoscopy findings were unremarkable. However, vaginocopy with the flexible cystoscope demonstrated a subtle area of anterior vaginal wall granulation tissue and a small focus of underlying mesh extrusion. She was treated with topical estrogens with the understanding that sling excision would be necessary if the area failed to heal.

CASE 6

A healthy 66-year-old woman who underwent the ObTape sling procedure complained of yellow vaginal discharge. Seven months postoperatively, she was diagnosed with a midline mesh extrusion and was scheduled to have the mesh removed under anesthesia.

COMMENT

Numerous sling techniques have been developed over the years in the quest to find one with optimal efficacy and minimal morbidity. Von Giordano introduced the concept of slings in 1907 using the gracilis muscle.¹ McGuire and Lytton⁸ popularized the use of autologous fascia in the late 1970s. Subsequently, a myriad of materials have been introduced, including autograft, allograft, and xenograft slings. Most recently, synthetic materials have emerged as alternatives.

Synthetic slings have gained popularity because they eliminate the need for harvesting and offer freedom from autolysis and prion considerations, with cure/improvement rates in the 90% range.⁹ However, they have been associated with greater rates of urethral erosion and vaginal extrusion.^{4,5} Although urethral erosions are usually due to technical errors, including excessive tension and/or unrecognized urethral injury, vaginal extrusions are usually due to subclinical infections or poor incorporation/integration of the sling material. The ProteGen system, a woven polyester-based sling, has been associated with very high rates of erosion (50% vaginal extrusion and 20% urethral erosion), culminating in a Food and Drug Administration recall in 1999.¹⁰

The transobturator technique was pioneered in 1999 by Delorme⁷ in France and was introduced to the European market by Mentor's Porges division. The transobturator approach was conceived to avoid the potential perils of retropubic placement in patients with prior pelvic surgery. The original European product, the Uratape, was a polypropylene mesh with a silicone-coated suburethral zone. Because of the high incidence of vaginal extrusion associated with the Uratape, it was withdrawn from the market and replaced with the ObTape. The ObTape mesh consists of a thermal-linked (nonwoven) monofilament polypropylene with small pores. The success rate of the ObTape has been similar to other available suburethral slings, with cure in the 90% range.¹¹

That the ObTape mesh is nonwoven makes it minimally elastic and rather stiff. In terms of elasticity, the ObTape is very similar to the Tyco Intra-Vaginal Slingoplasty sling, which has also been associated with high rates of vaginal mesh extrusion, ranging from 6% to 15%.¹²⁻¹⁵ In my series of Tyco Intra-Vaginal Slingoplasty slings, 6 (17%) of 35 patients experienced such complications.

Increasing evidence has shown that the inherent mesh characteristics, including material, filament, pore size, weave, and elasticity, create the differences among the myriad of commercially available slings and may engender complications such as vaginal extrusion.^{10,16,17} The success of any syn-

thetic sling is predicated on its satisfactory integration and incorporation, attributed to tissue in-growth of fibroblasts and macrophages between the polypropylene filaments. Macropore monofilament polypropylene material has the most compelling history of safety and biocompatibility compared with polytetrafluoroethylene, polyester, or silicone.⁶ Monofilament is clearly superior to multifilament insofar as the smaller interstices between the braided polypropylene multifilaments are more likely to harbor bacteria and impair tissue in-growth and integration. Bafghi *et al.*¹⁸ demonstrated a 7.4% infection rate with multifilament slings versus 0% with monofilament slings. Pore size is an important factor allowing tissue in-growth, collagen deposition, and integration. The ObTape has small pores, approximately 50 μm in diameter, that may be more apt to contain bacteria and impair fibroblast and macrophage in-growth and integration.¹⁹ This is in contrast to the Gynecare, American Medical Systems, and Boston Scientific products, which have macropores greater than 80 μm that may better allow for incorporation. Another key difference among the various slings is elasticity. The ObTape sling has low elasticity (less than 5%), does not require a covering sheath, and is, therefore, easy to re-tension. In contrast, the TVT-O, Monarch, and Obtryx slings are elastic (20% to 30%), require a covering sheath, and are more difficult to re-tension once the sheath has been removed. Stiff, nonwoven, inelastic synthetic slings may not conform to the surrounding tissue as well as the more elastic slings, further interfering with integration.¹⁶ The more elastic slings seem to adhere and conform to the underlying tissues better than the inelastic slings, similar to the way plastic cling wrap stretches and conforms to food items compared with the way wax paper does.

Droupy *et al.*²⁰ reported that 2 (2.2%) of 90 and Costa *et al.*²¹ that 6 (8.2%) of 73 patients had vaginal mesh extrusion associated with the Mentor transobturator tape. In 2004, 76 cases were reported of vaginal mesh extrusion associated with the Mentor ObTape sling, as detailed on the Food and Drug Administration web site that lists adverse events: <http://www.accessdata.fda.gov/scripts/cdrh/cfdocs/cfMAUDE/search.cfm>.

I have reported on a series of patients who experienced vaginal extrusions after transobturator placement of a Mentor ObTape sling. All patients presented with vaginal discharge. One patient developed an obturator abscess. Of the six patients, 5 required surgical removal of some or all of the sling material. All patients who underwent surgical excision had resolution of their symptoms. Others have reported similar symptoms, as well as irritative lower urinary tract symptoms, suprapubic pain, urinary infection, and hematuria.¹⁶ A high degree of suspicion should be maintained in pa-

tients with the preceding symptoms after sling operations. A careful pelvic examination with bright, focused illumination and the posterior vaginal wall retracted should be undertaken to rule out extrusion. Cystoscopy should be done to evaluate for urethral erosion. In cases with a high index of suspicion when the pelvic examination is unrevealing, vaginoscopy has proved to be a helpful diagnostic tool, particularly when the extrusion is subtle.

Two patients were young, premenopausal, and in excellent health with no risk factors for impaired vaginal healing. However, the other patients were older and had obvious risk factors, including obesity, diabetes, prior anti-incontinence surgery, postmenopausal status, and perhaps most importantly, evidence of impaired vaginal healing after prior sling surgery.

The treatment of 5 patients in this study required surgical excision. Some investigators have advocated immediate surgical removal of the extruded sling material.¹⁷ Kobashi and Govier¹⁹ recently reported on the role of conservative management in mesh erosions. They concluded that conservative management has a role in small erosions involving autografts, allografts, or loosely woven mesh, with surgical treatment considered if no improvement has been seen by 3 months.¹⁹

To paraphrase Stanton,²² "New techniques always raise the specter of initial biased enthusiasm, entrepreneurial haste from manufacturers and enthusiastic surgeons anxious to publish. These papers are often anecdotal, poorly controlled, and have inadequate outcome measures and length of follow-up. Ultimately, articles on complications are published, leading to the downfall of the procedure."

CONCLUSIONS

Stress urinary incontinence has emerged as a highly prevalent medical condition and, as such, has created a large and competitive marketplace for "new age," commercially available slings. The Mentor ObTape sling is one of the many available sling options that is effective in curing or improving stress incontinence; however, a troubling incidence of impaired vaginal healing and mesh extrusion has been recognized. The low elasticity and relatively small pore size of the monofilament polypropylene may predispose the ObTape system to greater rates of such complications. Because of a high rate of defective vaginal wound healing and mesh erosion, particularly in healthy patients with well-estrogenized vaginas and no risk factors for compromised healing, precaution should be exercised when considering using the Mentor ObTape sling for suburethral surgery. Patients with risk factors for impaired vaginal healing, including obe-

sity, diabetes, prior evidence of compromised vaginal healing, or atrophic vaginal epithelium, should not be considered for the Mentor ObTape sling. In the presence of such risk factors, it would be prudent to consider using those slings with the most favorable biomechanical properties and greatest likelihood of biocompatibility and successful integration: a nonsynthetic sling, an elastic, macropore monofilament polypropylene sling, or a composite sling with an absorbable suburethral component and synthetic lateral components.

REFERENCES

1. Westney OL, and McGuire EJ: Pubovaginal slings, in Hurt GW (Ed): *Urogynecological Surgery*. Philadelphia, Lippincott Williams & Wilkins, 2000, pp 93–95.
2. Petros PE: The intravaginal slingoplasty operation, a minimally invasive technique for cure of urinary incontinence in the female. *Aust NZ J Obstet Gynecol* 36: 453–461, 1999.
3. Ulmsten U, and Petros P: Intravaginal slingoplasty (IVS): an ambulatory surgical procedure for the treatment of female urinary incontinence. *Scand J Urol Nephrol* 29: 75–82, 1995.
4. Weinberger MW, and Ostergard DR: Long-term clinical and urodynamic evaluation of the polytetrafluorethylene suburethral sling for treatment of genuine stress incontinence. *Obstet Gynecol* 86: 92–96, 1995.
5. Gilberti C, and Rovida S: Transvaginal bone-anchored synthetic sling for the treatment of stress urinary incontinence: an outcomes analysis. *Urology* 56: 956–961, 2000.
6. Morgan JE: A sling operation using Marlex polypropylene mesh for treatment of recurrent stress incontinence. *Am J Obstet Gynecol* 106: 369–377, 1970.
7. Delorme E: Transobturator urethral suspension: minimally invasive procedure in the treatment of urinary stress incontinence in women. *Prog Urol* 11: 1306–1313, 2001.
8. McGuire EJ, and Lytton B: Pubovaginal sling for stress incontinence. *J Urol* 119: 82–84, 1978.
9. Young S, Howard A, and Baker S: Mersilene mesh sling: short and long-term clinical and urodynamic outcomes. *Am J Obstet Gynecol* 185: 32–40, 2001.
10. Kobashi KC, Dmochowski R, Sharron LM, *et al*: Erosion of woven polyester pubovaginal sling. *J Urol* 162: 2070–2072, 1999.
11. Delorme E, Droupy R, De Tayrac R, *et al*: Transobturator tape (Uratape): a new minimally-invasive procedure to treat female urinary incontinence. *Eur Urol* 45: 203–207, 2004.
12. Baessler K, Hewson A, Tun R, *et al*: Intravaginal sling distress (abstract). Presented at the International Continence Society Congress, Florence, Italy, 2003.
13. Pifarotti P, Meschia M, Gattei U, *et al*: Multicenter randomized trial of tension free vaginal tape (TVT) and intravaginal slingoplasty (IVS) for the treatment of stress urinary incontinence in women (abstract). Presented at the ICS and IUGA 494, 2004.
14. Glavind K, and Sander P: Erosion, defective healing and extrusion after tension-free urethropexy for the treatment of stress urinary incontinence. *Int Urogynecol J* 15: 179–182, 2004.
15. Meschia M, Pifarotti P, Bernasconi F, *et al*: Multicenter randomized trial of TVT and IVS for the treatment of stress urinary incontinence in women (abstract). Presented at the International Continence Society Congress, Florence, Italy, 2003.
16. Comiter CV, and Colegrove PM: High rate of vaginal extrusion of silicone-coated polyester sling. *Urology* 63: 1066–1070, 2004.
17. Clemens JQ, DeLancey JO, Faerber GJ, *et al*: Urinary tract erosions after synthetic pubovaginal slings: diagnosis and management strategy. *Urology* 56: 589–595, 2000.
18. Bafghi A, Trastour C, Benizri E, *et al*: Comparison between monofilament and multifilament polypropylene tapes in urinary incontinence (abstract). Presented at the International Continence Society and International Uro-Gynecological Association Annual Meeting, Buenos Aires, August 2004.
19. Kobashi KC, and Govier FE: Management of vaginal erosion of polypropylene mesh slings. *J Urol* 162: 2242–2243, 2003.
20. Droupy S, De Tayrac R, Delmas V, *et al*: Trans-obturator tape (TOT) for the treatment of female stress incontinence (abstract). Presented at the EAU Conference, Vienna, 2004.
21. Costa P, Ballanger P, Grise P, *et al*: Trans-obturator tape (TOT) for the treatment of female stress incontinence: preliminary results of a prospective multicenter register (abstract). Presented at the International Continence Society Annual Meeting, Florence, 2003.
22. Stanton SL: Some reflections on tension-free vaginal tape—a new surgical procedure for the treatment of female urinary incontinence. *Int Urogynecol J* 12: S1–S2, 2001.